HIATAL CLOSURE – NEW TRENDS IN LAPAROSCOPIC ANTIREFLUX SURGERY

F. A. Granderath[1] • C. T. Frantzides[2] • M. A. Carlson[3]

1 Department of General Surgery, Hospital Zell am See, Austria
2 Minimally Invasive Surgery Center, Evanston Northwestern Healthcare, Evanston, Il, USA
3 Department of Surgery, University of Nebraska Medical Center, Omaha, NE, USA

Introduction

Gastroesophageal reflux disease (GERD) has proven to be the most common upper gastrointestinal disorder in the western world with 10% of patients having daily symptoms [1], [2]. In many patients, GERD is associated with the presence of a hiatal hernia. The differences between the three traditional types of hiatal hernia regarding their morphological characteristics as well as the symptomatic correlation with GERD have to be considered. The most comprehensive classification recognizes three types of hiatal hernias. Type-I hiatal hernias, the classical sliding hiatal hernias, are characterized by transdiaphragmatic migration of the gastroesophageal junction and the proximal stomach toward the mediastinum. Type-I hiatal hernias are proven to be most common (80–90% of all types), particularly when the hernia is small. In type-II hiatal hernias or paraesophageal hernias, the gastroesophageal junction remains below the diaphragm in its normal position and the gastric fundus herniates alongside the esophagus into the mediastinum. The type-III hiatal hernias are a combination of both type-I and -II hernias. The gastroesophageal junction is above the diaphragm, and the gastric fundus herniates alongside the esophagus (*Figs. 1–3*). More than 80% of all paraesophageal hernias are considered to be type-III hiatal hernias.

Depending on these morphological entities, these three types show several symptomatic and clinical differences. A type-I hiatal hernia often causes characteristic GERD symptoms such as heartburn and regurgitation. Considerations regarding surgical therapy for this hernia type depends on the presence of GERD symptoms; therefore, the most common indication for surgery in type-I hiatal hernia is persistent GERD symptoms recalcitrant to medical therapy. A type-II hiatal hernia also can be accompanied by GERD symptoms, but this hernia type is typically associated with chest pain, dysphagia, pulmonary problems, nausea or bleeding, which are caused by the gastric herniation. Although paraesophageal hernia is a rare condition, it is associated with a rather high incidence of complications.

In case of axial rotation of the gastric fundus, the risk for intrathoracic strangulation and gastric volvulus with eventual incarceration and necrosis is increased. Therefore, most authors recommend a surgical management of paraesophageal hernia, even in patients without symptoms. The minimally invasive approach to paraesophageal hernia repair has become the standard of care for surgical management of this problem. Several studies have shown that laparoscopic paraesophageal hernia repair is associated with a lower incidence of morbidity, a shorter hospital stay, and a shorter recovery period compared to open repair [3]. Additionally, most authors agree that the laparoscopic

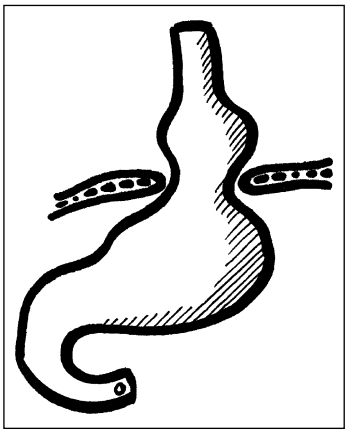

Fig. 1. Type-I hiatal hernia

approach allows better visibility and higher dissection of the intrathoracic esophagus. Whether performed open or laparoscopically, however, paraesophageal hernia repair is associated with a high recurrence rate. Recent reports have shown the laparoscopic approach in particular has a higher recurrence rate than the open approach, with recurrence rates in the former up to 42% [4]. Due to this high recurrence rate, several technical details have been considered to minimize the rate of recurrent hiatal herniation. Some of these details are still a matter of controversy; for example the complete removal of the hernia sac, the need to perform an antireflux procedure, or the performance of a gastropexy are frequent topics of discussion [5], [6]. The main question, however, has to be whether to perform the hiatoplasty with simple interrupted sutures or with prosthetic material.

During the past few years it has been shown that hiatal closure also has become a central point in laparoscopic antireflux surgery for GERD [7]. The causes of failure of an antireflux procedure are multiple, but the most frequent cause has proven to be the recurrent hiatal hernia with consecutive intrathoracic herniation of the fundic wrap into the mediastinum [8]. Typical symptoms of an intrathoracic wrap herniation are persistent or recurrent reflux, dysphagia, or the combination of both. The combination of these symptoms and this anatomic complication leads to redo-surgery in most of these patients [9]. In a large review of more than 10.000 laparoscopic antireflux procedures, it was documented that postoperative intrathoracic wrap herniation was the most common intraoperative finding during redosurgery for the failed antireflux procedure [10].

Some possible patient-related and procedure-related mechanisms for postoperative intrathoracic wrap migration include inappropriate postoperative activities of the patients immediately after surgery, inadequate mobilization of the esophagus, inadequate crural closure secondary to widely spaced crura sutured under tension, or a postoperative rupture of the cruroplasty due to continuous excursion of the diaphragm.

Crural closure has become a relevant problem in laparoscopic antireflux surgery, as well as during laparoscopic paraesophageal hernia repair. To solve this problem, some authors have advocated the use of prosthetic material for crural closure in both laparoscopic paraesophageal hernia repair and laparoscopic antireflux surgery. The concept of using prosthetic meshes is based upon the lessening of tension on the hiatal crura or the reinforcement of simple sutured crura to prevent postoperative hiatal disruption. Since the first description of prosthetic hiatal closure by Kuster in 1993 [5], a number of techniques have been published. There has debate regarding the shape of the mesh, the material of the mesh, the position and placement of the mesh, and especially whether a prosthetic hiatal reinforcement has to be tension-free. Additionally, there is no agreement regarding the question of selective versus routine use of mesh. Some authors recommend the routine use of prosthetic mesh in order to prevent tension on the hiatal crura and therefore decrease hiatal hernia recurrence. Other authors use mesh selectively, e.g., in patients in whom a

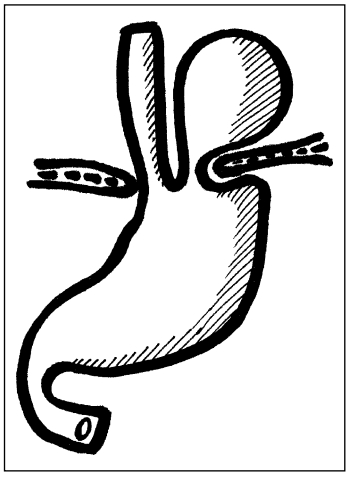

Fig. 2. Type-II hiatal hernia



Fig. 3. Type-III hiatal hernia

sufficient tension-free hiatal closure cannot be achieved with simple sutures.

For some authors, the indication for reinforcement of the hiatal crura with prosthetic material depends on the size of the hiatal defect. Another point of controversy focuses on the shape and material of the prosthetic mesh. Some authors routinely use polypropylene meshes for hiatal closure, believing that polypropylene rapidly incorporates and that the developing scar tissue strengthens the muscular fibers of the hiatal crura. Other authors discourage the use of polypropylene due to the development of visceral adhesions and the risk of intestinal fistula [11]. On the other hand polytetrafluoroethylene (PTFE) has been recommended for hiatal closure because of its low adhesive potential.

Techniques and results of prosthetic meshes for closure of the esophageal hiatus

Several techniques have been described for prosthetic closure of the hiatal crura. Basically, two different approaches have to be differentiated: mesh repair without primary sutured crura ("tension-free") or mesh repair with primary cruroplasty.

The first study regarding laparoscopic large hiatal hernia repair with hiatal mesh prosthesis was published by Kuster and Gilroy in 1993 [5]. These authors preferred tension-free anterior repair of the hiatal defect. In 6 patients with large paraesophageal hernia, the hiatal crura could not be sutured anterior to the esophagus without significant tension. Therefore a Mersilene® mesh was placed on the hiatus as an anterior onlay patch, overlapping the hiatal crura about 2 cm in all directions. The mesh was secured to the crural edges with staples. No intraoperative or postoperative mesh-related complications occurred during a follow-up period of 8–22 months. Postoperative gastrointestinal series showed no evidence of postoperative hernia recurrence; however, 2 patients had slippage of a small part of the posterior segment of the fundus. None of these patients developed postoperative mesh-related dysphagia or GERD symptoms during the follow-up period.

A similar technique has been used by Paul et al [12] in 3 elderly patients. A 5 × 10 cm Gore-tex® mesh (PTFE) was cut to cover the hiatal defect, and then was placed as an anterior onlay patch. The mesh was secured at the lower mesh edges, and then sutured in a running fashion up to the top of the mesh (*Fig. 4*). In this small series there were no complications, and for a mean follow-up period of 10 months there were no hernia recurrences.

Another technique of tension-free hiatal closure has been avocated by Basso and colleagues [13]. In 65 patients who underwent laparoscopic Nissen fundoplication with simple sutured hiatal closure the authors experienced a hiatal hernia recurrence rate of 13.8% during a mean follow-up period of 48.3 months. After reviewing the videotapes of these patients, it became clear that the crural sutures were under tension, and that hiatal disruption led to postoperative intrathoracic migration of the fundic wrap. Due to these findings, the authors began using a 3 × 4 cm polypropylene mesh for posterior hiatal reinforcement.The mesh was secured with staples on the upper side and on the lateral sides of both crura as a tension free hiatoplasty (*Fig. 5*). This technique was used in a subsequent group of 67 patients who underwent laparoscopic Nissen fundoplication for GERD. During a mean follow-up period of 22.5 months, the authors saw no complication related to the prosthetic mesh nor hiatal hernia recurrence.

An interesting technique to achieve a tension-free hiatal closure has been described by Huntington et al [14]. If a tension-free crural closure with simple sutures was nor possible, then a relaxing incision on the

Fig. 4. Tension-free anterior repair

diaphragm was performed to gain crural mobility for a simple sutured hiatoplasty. The diaphragmatic defect of the relaxing incision then was closed with a polypropylene patch (*Fig. 6*). This technique was used successfully in 8 patients with paraesophageal hernia; there was no recurrence during a follow-up period of 8 months.

Champion et al [15] preferred prosthetic reinforcement of primarily sutured crura. Similar to Basso et al [13], these authors used a 3 × 5 cm polypropylene mesh for posterior hiatal closure. After placing interrupted permanent sutures posteriorly to the esophagus, the polypropylene mesh was placed as an onlay prosthesis, and then fixed with a hernia stapler along the crural edges. The mesh was secured further with a centrally placed permanent mattress suture; this ensured that the upper edge of the mesh was positioned at least 1 cm below the upper edge of the crural repair (*Fig. 7*). This technique was performed in 52 consecutive patients with symptomatic GERD and a large hiatal/paraesophageal hernia. During a mean postoperative follow-up period of 25 months, only one patient developed a postoperative intrathoracic wrap migration; this was caused by violent retching in the recovery room after surgery. Later on, this patient underwent redo-surgery due to recurrent GERD symptoms. Importantly, no mesh migrations or visceral erosion occurred in this series of patients.

In a recently published article by Keidar and Szold [16], the authors use a circular mesh in a similar shape as Frantzides et al [17]. Out of a sample of 33 patients, a group of 10 patients with large paraesophageal hernias underwent laparoscopic prosthetic hiatal repair. The simple cruroplasty then was reinforced with Gore-tex® mesh in six patients and Prolene® mesh in four patients. The mesh was precut to an oval sheet, placed around the esophagus and then fixed to the diaphragm using a hernia stapler (*Fig. 8*). During a follow-up period of 46–76 months, the satisfaction score was good to excellent in the majority of patients. Only 1 patient of the mesh-repaired patients developed a hiatal hernia recurrence in contrast to 4 patients who underwent repair without mesh. No complications related to the use of the mesh were seen in this study.

Casaccia et al [18] published their experience with an innovative physiological composite "A" – shaped mesh. The authors first performed a physical and geometrical analysis of the esophageal hiatus with a theoretical model. Based on their findings regarding the physiological strengths of the hiatal crura with or without direct sutures, they performed an anatomical study on 20 cadavers to verify the anatomical findings of their theoretical model. As a result, they developed a special "A" shaped PTFE – mesh (BARD® Composix mesh)

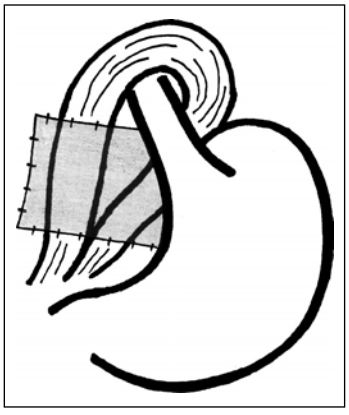

Fig. 5. Tension-free posterior repair

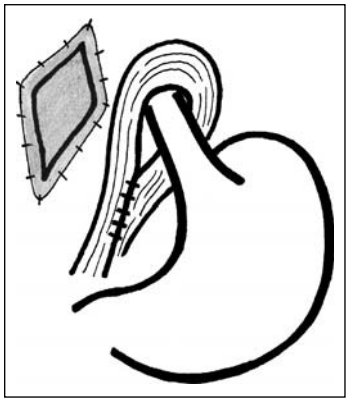

Fig. 6. Tension-free sutured repair

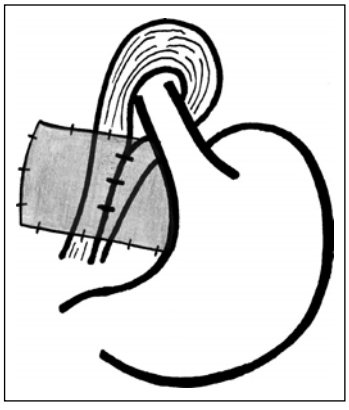

Fig. 7. Sutured crura and posterior mesh repair

which, when positioned over the hiatal defect, was intended to effect closure similar to the physiological condition (*Fig. 9*). In 8 patients with large type-II and type-III hiatal hernia, laparoscopic repair was performed with this composite "A" shaped PTFE mesh. Intraoperatively, the authors found that the mesh fit well in the hiatal region, with good handling and easy placement on the diaphragm. Postoperative dysphagia occurred in 2 patients for up to 3 months after surgery, but no recurrence was observed during an average follow-up period of 8 months.

Based on the possibility of mesh-related complications such as esophageal stricture, mesh migration, or visceral erosion, Oelschlager et al [19] advocated the use of a new type of mesh made from porcine small intestine submucosa (SIS) for laparoscopic repair of paraesophageal hernias. The authors closed the hiatal crura with interrupted 2−0 silk sutures, and then positioned a U-shaped 7 × 10 cm four-ply Surgisis® mesh posteriorly so that the mesh covered the crural repair. The mesh was secured with interrupted silk sutures to the diaphragm (*Fig. 10*). This technique has been used in 9 patients with large paraesophageal hernias that could not be closed without tension. In 8 patients who were available for follow-up, only 1 had a small (2 cm) recurrent hiatal hernia on barium esophagram; this recurrence was asymptomatic. Another patient had to undergo pneumatic dilatation for persistent mild dysphagia, but without signs of anatomic failure on endoscopy or barium swallow. There were no other complications in this series.

Another approach to crural closure with biomaterial has been described by Varga et al [20]. In this study, the hiatoplasty was performed with the ligamentum teres in addition to simple sutures. After closing the hiatal crura with nonabsorbable interrupted sutures, the mobilized ligamentum teres was pulled between the closed crura and posterior esophagus, and then sutured to the crura. This created a U-shaped hiatal onlay reinforcement (*Fig. 11*). This technique was performed in 4 patients with type-III hiatal hernia. There were no perioperative complications related to this kind of hiatoplasty. One patient had minor episodic epigastric pain postoperatively; otherwise, all patients relieved of symptoms. No recurrent hiatal hernia occurred during follow-up of 3–11 months.

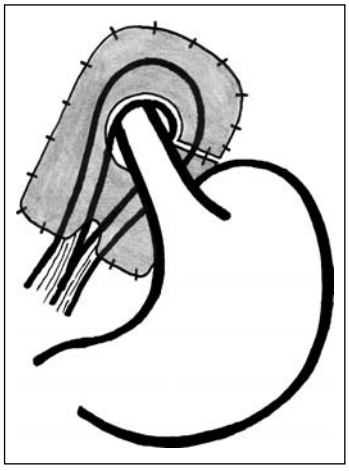

Fig. 9. Simple cruroplasty and "A"-shaped mesh repair

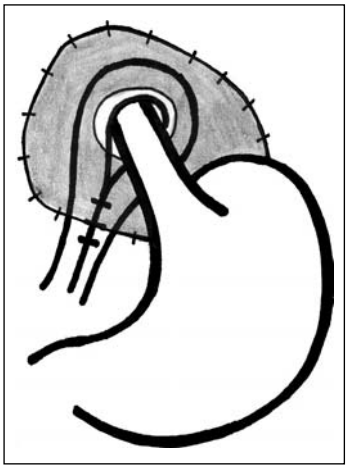

Fig. 8. Simple cruroplasty and circular mesh repair

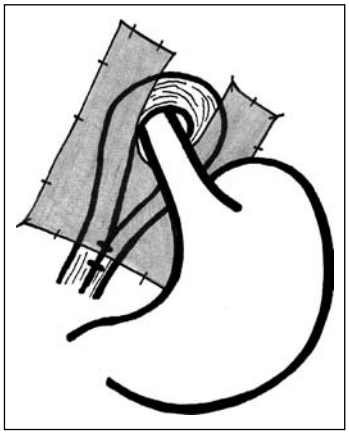

Fig. 10. Simple cruroplasty and SIS® mesh repair

Own experience

The high rate of postoperative intrathoracic wrap migration after laparoscopic antireflux surgery prompted us to use prosthetic meshes for crural closure in December 1998. In all patients who underwent laparoscopic antireflux surgery at our surgical unit, hiatal hernia recurrence with intrathoracic wrap migration was the most common cause of anatomic failure after primary laparoscopic antireflux surgery. In over 70% of patients who underwent laparoscopic refundoplication after primary failed antireflux surgery, intrathoracic wrap migration was found as the reason for failure.

In a prospective non-randomized trial [21] we compared 361 patients with GERD who underwent laparoscopic Nissen or Toupet fundoplication with simple crural closure to 170 GERD patients who underwent laparoscopic antireflux surgery with simple hiatal closure reinforced with polypropylene mesh. In the group of patients who underwent primary cruroplasty, the number of sutures depended on the size of hiatal hernia; in these patients, the crura were approximated with 2–4 interrupted nonbasorbable polyfilament sutures (*Figs. 12* and *13*).

In the cruroplasty and mesh group, the crura were approximated with simple interrupted sutures as above. Additionally, a 1 × 3 cm section of polypropylene mesh (cut from a 10 × 15 Prolene® mesh for groin hernia repair) was placed on the sutured crura as a posterior onlay and sutured with one stitch on the lateral sides of both the right and the left crus (*Figs. 14* and *15*).

Follow-up examinations were performed 6 weeks, 3 months and 1 year after surgery. After 1 year of follow-up, a significant difference in the postoperative occurrence of intrathoracic wrap migration was found. In the initial group with non-mesh hiatoplasty, a postoperative intrathoracic wrap migration occurred in 6.1% of patients compared to 0.6% of patients who underwent cru-

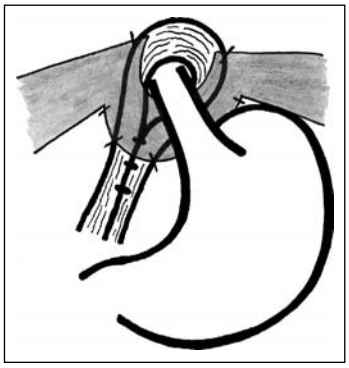

Fig. 11. Simple cruroplasty and ligamentum teres repair

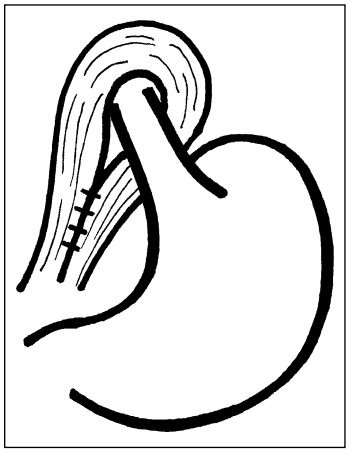

Fig. 12. Simple cruroplasty

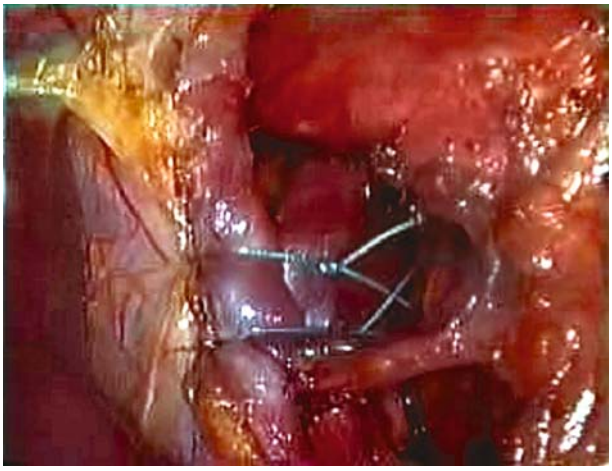

Fig. 13. Simple cruroplasty

ral closure with polypropylene mesh onlay. A significant difference also occurred in the incidence of postoperative dysphagia. Patients with mesh-cruroplasty had a dysphagia rate of 35.3% compared to 19.8% in the non-mesh group 3 months after surgery; however, the dysphagia rate resolved at the 1 year visit and was not different between the two groups.

These findings were re-evaluated in another non randomized trial [22], in which 100 GERD patients with simple crural closure were compared to 100 GERD patients with simple closure reinforced with the 1 × 3 cm polypropylene mesh hiatoplasty. The postoperative dysphagia rate and its impact on quality of life was evaluated for a period of 12 months after surgery. The postoperative dysphagia rate was significantly higher in the mesh-group at 3 month follow-up, but again decreased to comparable values at 1 year follow-up. Apart from these results, patients quality of life (GQLI) significantly improved after surgery in both groups. This improvement remained stable up to one year postoperatively, was comparable between the two groups, and similar to values from a healthy control group.

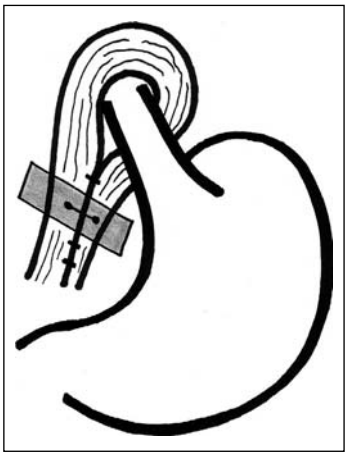

Fig. 14. Simple cruroplasty and posterior 1 × 3 cm polypropylene mesh repair

To verify these findings, a prospective randomized study was performed on 100 GERD patients scheduled for laparoscopic Nissen fundoplication [23]. Fifty patients were prospectively randomized to laparoscopic 360° floppy Nissen fundoplication with simple hiatoplasty, and fifty were randomized to laparoscopic 360° floppy Nissen fundoplication with 1 × 3 cm polypropylene mesh onlay. Follow-up of 12 months was obtained in all patients. Three months after surgery, a significant difference in postoperative intrathoracic wrap migrations was observed. Five patients (10%) of the non-mesh group had a recurrence compared to 1 patient (2%) of the mesh-group. Twelve months after surgery, the recurrence rates increased to 4 patients (8%) in the mesh-group and 13 patients (26%) in the non-mesh-group. In addition, patients with prosthetic hiatal closure again had a higher dysphagia rate at the 3 months visit, as previously observed.

A different type of prosthetic mesh was used in 24 patients who underwent laparoscopic refundoplication in our surgical unit for a failed primary antireflux surgery. The cause of failure in all of these patients was a symptomatic intrathoracic wrap mig-ration [24]. The failed hiatal repair was primarily approximated with interrupted nonabsorbable sutures and then reinforced with a circular precut polypropylene mesh. The mesh was cut out with a 3–4 cm "keyhole" as described by

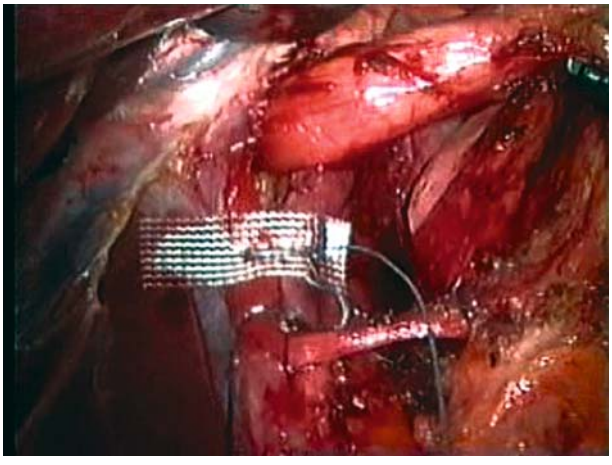

Fig. 15. Simple cruroplasty and posterior 1 × 3 cm polypropylene mesh repair

Frantzides and Carlson [25]. The mesh was placed around the esophagus and secured to the diaphragm and crura with a hernia stapler (*Figs. 16* and *17*). All patients were followed for 12 months after surgery, and no one had a hiatal hernia recurrence. We have had no evidence of any mesh-related complications such as erosion, migration, or visceral perforation in our patients.

We also are working on other alternatives for hiatal closure. The higher dysphagia rate in patients with hiatal mesh prosthesis has led us to use a special "V" shaped Composix mesh (Crurasoft®, BARD) for large hiatal hernia repair. After dissection of the hiatal crura, the mesh is brought into the abdomen and positioned on to the crura as a tension-free posterior onlay. The mesh is fixed with interrupted sutures on the edges of the mesh and secured with staples on the lateral side of the mesh (*Figs. 18* and *19*). The advantages of this mesh type have been ascribed to the combination of two clinically proven materials: BARD® mesh on the one side for maximum tissue ingrowth and ePTFE on the other side for minimal visceral adhesions.

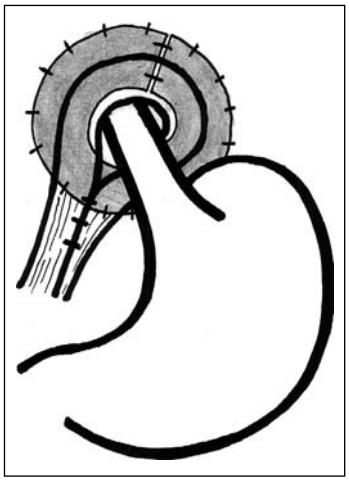

Fig. 16. Simple cruroplasty and circular polypropylene mesh repair

In addition, we are participating in a multicenter study regarding the use of PARIETEX®, a newer mesh, which, similar to the Composix mesh, combines two different materials. Parietex® composite mesh has a three-dimensional weave of polyester on the one side with a hydrophilic collagen material on the other side. The resorbable collagen side has been designed for the prevention of intrabdominal adhesions to the mesh in the early postoperative period. The polyester side guarantees rapid tissue ingrowth with permanent reinforcement. In conjunction with the participating colleagues and the manufacturer, we have designed a special "V" shape of this mesh particularly for laparoscopic closure of the hiatal crura. The mesh is used both for tension-free hiatal closure (*Figs. 20* and *21*) and as an additional reinforcement of primary sutured hiatal crura. Positioned as a posterior onlay prosthesis, the mesh is secured to the diaphragm with a hernia stapler.

Based on our previous findings and experiences, we are developing a new kind of prosthetic mesh which specifically will be for hiatal closure. During laparoscopic refundoplication for primary failed hiatal closure, the fundic wrap often does not slip posterior to but also anterior to the esophagus. Therefore, in addition to posterior closure, the mesh should also cover the anterior diaphragmatic region to prevent postoperative anterior slippage. Circular meshes have proven

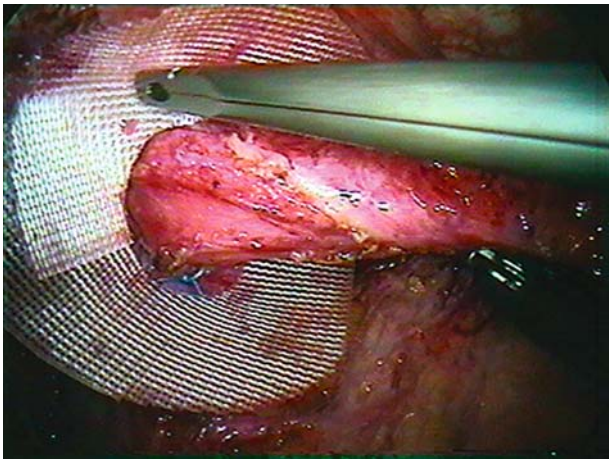

Fig. 17. Simple cruroplasty and circular polypropylene mesh repair

to be an effective method to prevent hiatal hernia recurrence in some studies. We have employed a "heart" shaped modification of this mesh with large anterior and posterior portions which completely cover the hiatal crura behind the esophagus. The esophagus lies in a 3–4 cm central keyhole, which is protected by a PTFE collar to prevent esophageal erosion by the mesh (*Fig. 22*).

Experience of Drs. Frantzides and Carlson

Our initial results with laparoscopic mesh-reinforced diaphragmatic hernia repair

To our knowledge, Dr. Robert Condon of the Medical College of Wisconsin (Milwaukee, Wisconsin, USA) was the first to address the problem of unacceptably high recurrence rate after (open) sutured hiatal herniorrhaphy by using a mesh-reinforced cruroplasty. Beginning in the latter 1970's, this surgeon (who was our mentor) instituted a policy of polypropylene onlay to the diaphragm for patients with large hiatal hernia with intrathoracic stomach [26]. His technique consisted of a sutured posterior cruroplasty onto which a sheet of Marlex® was placed, followed by a gastrostomy. In order to accommodate passage of the esophagus, a "keyhole" was cut in the center of the mesh. Over a fifteen year period, 44 patients with intrathoracic stomach were treated in such a manner. After a mean follow-up period of 52 months (range 2 months to 15 years), the clinical recurrence rate was zero [26]. At the time of its publication in 1998, this manuscript represented one of the largest series of prosthesis-reinforced diaphragmatic hernia repairs, either open or laparoscopic.

Encouraged with the result of open mesh repair of diaphragmatic hernia, we elected to perform the repair with a minimally invasive approach. We did have a concern with using a stiff prosthetic mesh (such as Marlex®) at the hiatus, because this mesh did erode into the esophagus in one patient from the open series [26]. Polypropylene mesh erosion into exposed bowel has been a frequent enough problem in mesh repair of anterior abdominal wall defects, especially in the presence of acute inflammation [27]. We believed that the use of PTFE at the hiatus might lessen the risk for erosive complications, since only a handful of cases have been published documenting PTFE as the cause or suspected cause of a bowel fistula (at the time we were contemplating such repairs, no reports of erosive complications

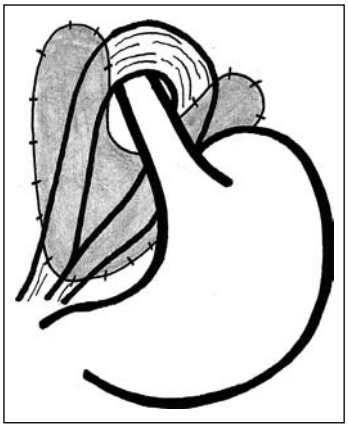

Fig. 18. Tension-free posterior Crurasoft® mesh repair

Fig. 19. Tension-free posterior Crurasoft® mesh repair

from PTFE could be found). Another theoretical concern we had was whether the use of mesh actually would be of benefit in the repair of diaphragmatic hernia. Our retrospective series suggested that utilization of mesh decreased hernia recurrence rate, but we did not have any controlled data that confirmed this. Therefore, after a small number of cases to demonstrate the feasibility of minimally invasive hiatal herniorrhaphy with PTFE onlay reinforcement [17], we embarked on a randomized controlled trial to test whether mesh placement reduced the recurrence rate after laparoscopic diaphragmatic hernia repair.

We hypothesized that a benefit from mesh placement most likely would be seen in patients with a large hiatal defect (which we defined as ≥ 8 cm). Seventy-two patients with gastroesophageal reflux disease and large defect hiatal hernia were enrolled into this trial [25]. The study population consisted of a subset of all patients (> 600) undergoing primary minimally invasive antireflux surgery under the care of Dr. Frantzides. The decision whether to enroll a patient into the study was made after intraoperative measurement of the hiatal defect. If the defect diameter was ≥ 8 cm, then the subject was randomized, and a simple posterior cruroplasty with or without PTFE onlay reinforcement (see below) followed by a floppy Nissen fundoplication was performed. After a mean follow-up period of 3.3 years, the recurrence rate in the cruroplasty-only group was 22% (i.e., 8 of 36), and the rate in the cruroplasty plus PTFE group was zero. There were no mesh-related complications. We concluded that PTFE reinforcement of posterior cruroplasty was indicated for hiatal defects ≥ 8 cm.

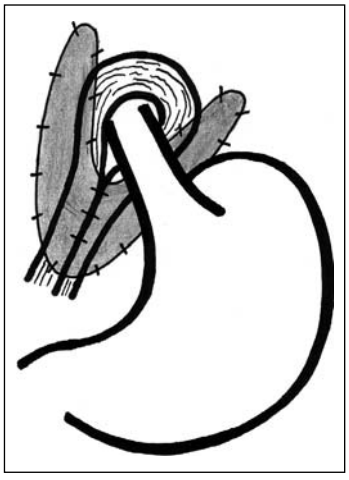

Fig. 20. Parietex® mesh repair

Our technique of laparoscopic mesh-reinforced hiatal hernia repair

Our technique of minimally invasive hiatal hernia repair has been described in detail elsewhere [28]. The patient is placed in a modified lithotomy position with 15–20° of reverse-Trendelenburg tilt, and the surgeon stands between the patient's legs. We employ five 10 mm ports; this gives us maximum flexibility in instrument choice, including atraumatic 10 mm tissue graspers (atraugrip grasper – Pilling and Weck Surgical, Ft. Washington, PA). The liver is retracted with an inflatable nontraumatic balloon retractor (Soft Wand atraumatic balloon, Southborough, MA). The contents of the hiatal

Fig. 21. Parietex® mesh repair

hernia (stomach, omentum, transverse colon, etc.) are reduced using the atraumatic grasper. The lesser omentum is then entered at the avascular area above the caudate lobe and the incision extended to the anterior arch of the crura. The hernia sac is reduced and excised. This dissection of the sac should be done meticulously so that pneumothorax is avoided. We advocate routine excision of the hernia sac; without such excision, the subsequent dissection can be difficult and confusing. The esophagus should be mobilized such that the distal 5 cm lies within the abdomen without tension. We prefer to employ a lighted esophageal bougie during this part of the procedure; this can aid in the identification of the esophagus, which can be a difficult task.

After the esophagus is fully mobilized, a posterior cruroplasty is performed with nonpledgeted, interrupted sutures of braided polyester. If an anterior hiatal defect is present at this point, then we also will a employ a 1–2 stitch anterior cruroplasty. A PTFE patch then is custom-cut from a larger sheet of mesh (see *Fig. 23*); a "keyhole" (3.5 cm circular defect) is cut into the center of the mesh to accommodate the esophagus (*Fig. 23*). The patch is introduced into the abdomen through a trocar (avoiding contact with the skin), and then applied as an onlay to the diaphragmatic repair, ensuring that the macroporous (rough) surface of the mesh faces the diaphragm. The prosthetic is anchored in place with a rigid laparoscopic hernia stapler (see *Fig. 24*). This 10 mm instrument fires titanium staples; we have found its performance optimal for securing PTFE to the diaphragm. The procedure is completed with a floppy 3-stitch, 2 cm-long Nissen fundoplication, performed over a 50–60 Fr bougie.

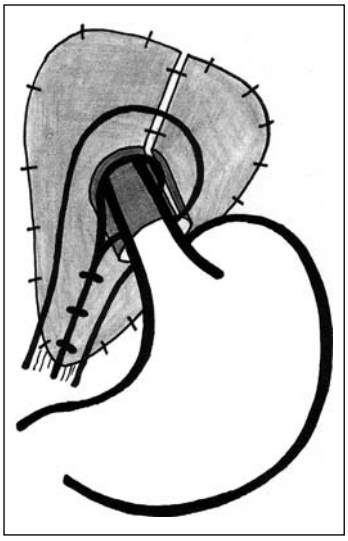

Fig. 22. The "Zell" mesh

There are issue regarding the technique of mesh fixation to the diaphragm; specifically, whether to apply the mesh as on onlay, or to perform a "tension-free" repair. We have preferred the former; that is, to complete a primary cruroplasty first, and then to cover the cruroplasty with an onlay patch. In this situation, the mesh acts as a buttress for the sutured cruroplasty, relieving the tissue repair from the forces of intraabdominal pressure, respiratory excursion, and so forth. In the tension-free repair, the crura are not approximated; the mesh bridges the native defect. At this point in time there is no evidence from the field of mesh hiatal herniorrhaphy to support the use of onlay repair over tension-free repair (or *visa versa*). Our preference for the onlay repair has been our practice pattern, and we have had and continue to have salutary results from this practice. Practically speaking, it is easier to staple the mesh in place around the esopha-

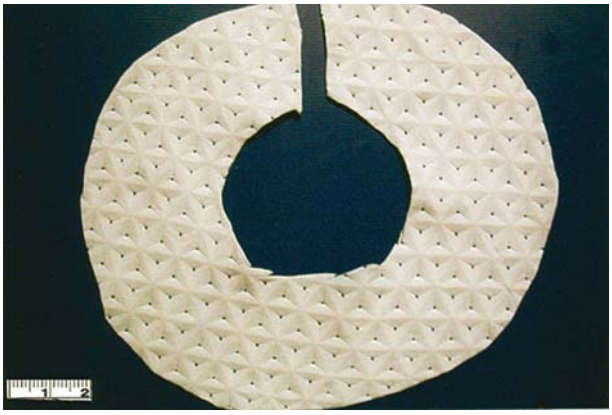

Fig. 23. PTFE onlay patch is constructed to have an oval shape with a horizontal diameter of 12 cm and anterior-posterior dimension of 10 cm. A 3.5 cm "keyhole" is made in the center of the mesh in order to accommodate passage of the esophagus

gus when it is surrounded by the sutured crura. In a small number of cases, it will be impossible to suture the crura together secondary to excessive tension, poor tissue, or other reasons. In these situations a tension-free application of the prosthetic should be employed. In the final analysis, it likely is the presence of the mesh itself (and not whether it is applied as an onlay or a bridge) which prevents hernia recurrence.

We believe that in order for the mesh to have an optimal effect (i.e., producing the lowest possible recurrence rate), the mesh should cover the repair with a large "overlap". That is, the mesh should extend beyond the crural margins by as much as the local anatomy will allow (see *Fig. B*). Practically speaking, extension of the mesh in this location is limited to the right by the inferior vena cava, anteriorly by the left lobe of the liver, posteriorly by retroperitoneal structures and to the left by the spleen. Thus caution should be taken to avoid injury to any of these structures. The importance of several centimeters of mesh extension beyond the entire circumference of a hernial defect has been borne out by a large amount of retrospective data from underlay repair of ventral herniorrhaphy, both open and laparoscopic [29], [30] For example, if a surgeon is faced with a 4 cm round-shaped ventral hernia, then the diameter of the mesh used in an underlay repair typically should be 8–10 cm, which permits a 2–3 cm extension of the mesh beyond the entire circumference of the defect. While it is difficult to satisfy these same criteria for mesh coverage of a hiatal defect, the precept of mesh overlap of the hernial defect should be kept in mind when applying this technique to a hiatal hernia.

The actual firing of the stapler can be a "tricky" maneuver, because unfortunate stapler deployment can injure the heart, which can result in fatal outcomes [31]. The precise technical details in stapling PTFE to the diaphragm with proximity of the heart are difficult to convey in written form. The surgeon must use enough pressure on the stapler to ensure that the staple penetrates the prosthesis and secures an adequate tissue bite, but not so much pressure that the staple penetrates the diaphragm and breaches the pericardium. The attainment of this skill is facilitated with training, anatomic knowledge, and experience.

Recent results with laparoscopic mesh-reinforced diaphragmatic hernia repair

Since the conclusion of our randomized trial [25] we have routinely employed PTFE mesh reinforcement during minimally invasive repair of large hiatal hernia. We have decreased our threshold for mesh usage to hiatal defects whose diameter is in the range of 5–6 cm. Our original indication for the utilization of PTFE reinforcement during hiatal herniorrhaphy was a defect size of ≥ 8 cm; this cut-off size is relatively large. Since we had an impressive difference in outcome between the control and mesh groups in our randomized trial [25] we felt justified in broadening the indication for mesh usage. Since 2000, we have performed 63 minimally invasive hiatal hernia repairs; PTFE was employed in 28 (44%) of these herniorrhaphies. Since 1992 sixty four patients have undergone laparoscopic large hiatal hernia repairs with placement of PTFE prosthesis. We have yet

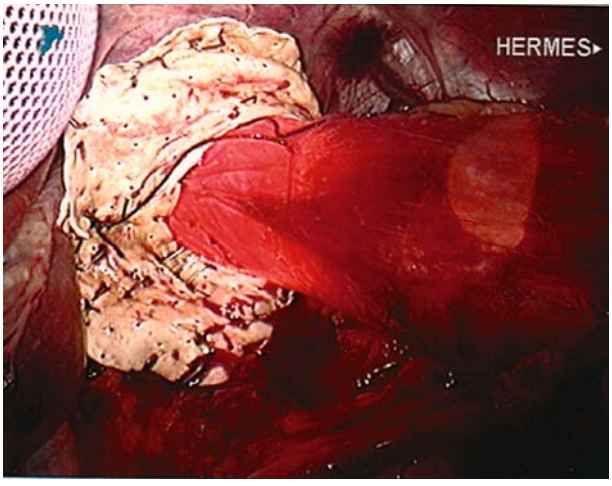

Fig. 24. Completed mesh repair of a hiatal hernia. The crura first were closed with simple sutures of 2−0 braided polyester, and then a patch as shown in the previous figure was applied to the cruroplasty (i.e., as an onlay) and stapled circumferentially in place. Note the extensive overlap of the repair by the mesh

to document a recurrence after mesh reinforcement of minimally invasive hiatal hernia repair with our technique described above. In addition, no patient has been documented to have mesh infection, erosion, or contraction ("mesh shrinkage" [32]). We have noted in the literature a few reported cases reports of PFTE erosion into a gastrointestinal lumen (see below), but this has not dissuaded us from using PTFE-onlay reinforcement of sutured cruroplasty for the repair of the large hiatal defect.

Complications of prosthetic hiatal repair

The use of prosthetic materials in surgery for gastroesophageal reflux disease and/or large hiatal hernia repair is accompanied by alow incidence of foreign body complications. For instance, the use of Teflon-pledgets in fundoplication has been associated with visceral erosion, foreign body migration, or gastroesophageal fistula after surgery [33]–[35].

In particular, a risk for complications related to the use of prosthetic materials for closure of the hiatal crura has been predicted by some authors. The focus is on the possibility of erosion or migration of the mesh into the esophagus or stomach, as well as complications due to severe mesh adhesions, infection, or the development of fibrotic strictures in the hiatal area. In a study by Carlson et al [26], one patient (2.3%) out of 44 who underwent open prosthetic hiatal closure for large hiatal hernia repair developed a mesh erosion into the esophagus 29 months after surgery. Edelman et al [36] reported one patient out of 5 who had to undergo revisional surgery after primary laparoscopic paraesophageal hernia repair with mesh. This patients had severe dysphagia due to esophageal stenosis secondary to mesh-induced fibrosis. Likewise, Trus et al [37] also saw one patient who had undergone primary laparoscopic mesh repair for paraesophageal hernia who then suffered from refractory postoperative dysphagia. During re-laparotomy the authors found a circular scar at the distal esophagus caused by the hiatal mesh. The mesh had to be excised, a myotomy was performed, and then the crura were approximated. Persistent postoperative dysphagia refractory to dilatations was reported by Van der Peet et al [38]. One patient who underwent laparoscopic hiatal hernia repair with Dacron mesh reinforcement had a significant fibrotic reaction to the mesh; This had to be removed during a reoperation. Another two patients with mesh-related complications were reported by Casabella et al [39]. One patient developed fibrotic damage at the hiatus postoperatively; the other patient had a mesh erosion into the esophagus. Both of these patients underwent redo-surgery and required distal resection of the esophagus because of the mesh intrusion into the lumen. Coluccio et al [40] also reported about one case who required resection of the distal esophagus due to a mesh-related complication. This patient underwent large hiatal hernia repair with the use of a PTFE prosthesis which subsequently migrated into the cardial lumen. During reoperation the mesh had to be removed, and the patient required a distal esophageal resection. A fatal complication was described by Kemppainen et al [31]. This patient had a large paraesophageal hernia with acute thoracic herniation and incarceration of the stomach, and underwent laparoscopic hiatal hernia repair with tension-free hiatoplasty using PTFE. Fixation of the mesh was undertaken with a hernia stapler. After surgery, this patient developed a cardiac tamponade caused by a stapler laceration of a coronary vein.

Although there has been a limited number of complications related to prosthetic mesh after laparoscopic antireflux surgery or large hiatal hernia repair, some authors recommend the use of biomaterials or autologous tissue to avoid any risk of complication secondary to prosthetic mesh. Varga et al [20] advocated the use of ligamentum teres for reinforcement of the hiatal crura in four patients with a hiatal hernia $\geq$ 6 cm. In a similar way, the successful use of biomaterial has been described by Oelschlager et al [19]. Nine patients underwent laparoscopic paraesophageal hernia repair with the use of a porcine small intestine submucosa (SIS) mesh for crural closure to avoid mesh-related esophageal or gastric injury.

Conclusion and future perspectives

In general, hiatal reinforcement with the use prosthetic meshes has proven to be a safe and effective procedure to prevent postoperative hiatal hernia recurrence and/or postoperative intrathoracic migration of the fundic wrap in both laparoscopic surgery for hiatal or paraesophageal hernia repair as well as

in laparoscopic antireflux surgery for gastroesophageal reflux disease. A few comparative studies and trials of laparoscopic hiatal closure with simple sutures versus mesh-hiatoplasty have shown, that patients with a prosthetic hiatal closure had a lower rate of postoperative hiatal hernia recurrences in comparison to patients with simple hiatal repair. Some patients with prosthetic hiatal closure, however, suffer from prolonged postoperative symptoms like dysphagia or chest pain; Fortunately, this resolves in most of the patients without further treatment. A true complication related to the use of prosthetic material for hiatal closure is a rare condition when the procedure is performed properly.

A consensus regarding a standard indication for the use of prosthetic mesh for hiatal closure does not exist at this time. Some authors advocate the use of prosthetic meshes empirically only in patients in whom a tension-free crural closure with simple sutures seems impossible. Some authors, however, employ prosthetic hiatoplasty in a more liberal matter. These authors agree that the primary indication for prosthetic hiatal closure should be the size of the hiatal defect. Dr. Frantzides (Chicago, USA) and Dr. Carlson (Omaha, USA) have reduced their original indication of hiatal defect ≥ 8 cm to a typical cut-off point of 5–6 cm. Other factors like body mass index or sociodemographic aspects may influence the indication somewhat, but the primary indication for them has remained the size of the hiatus. Dr. Szold (Tel Aviv, Israel) recommends the use of meshes in all patients with paraesophageal hernias, in all hiatal hernias > 4 cm, or in patients in whom the crura seem weak or damaged.

Regarding the characteristics of the mesh, most authors agree that the ideal mesh has to be easy to handle during laparoscopy, able to adhere to the diaphragmatic surface on the one side, and be benign to the visceral surface on the other side. It should be resistant to infection and to long-term contraction.

The shape of the mesh is still a matter of controversy. Most authors recommend a posterior onlay repair; others have advocated the use of circular prostheses with good results. This topic will be a matter of future research, especially when long-term results of published series are available. An overview of experts recommendations is shown in Table 2.

Table 1. Results of laparoscopic hiatal hernia repair with mesh prosthesis

Author (Ref.)	Publication (year)	Patients (n)		Mesh type	Repair	Follow-up (months)	Recurrence rate	
		Mesh	*Non-mesh*				*Mesh*	*Non-mesh*
Kuster [5]	J Laparoendosc Surg (1993)	6	–	Mersilene	LPEHR	8–22	0	–
Pitcher [42]	Arch Surg (1995)	2	10	PTFE	LPEHR(4), LARS(8)	–	0	0
Odsdottir [43]	Surg Endsoc (1995)	10	–		LARS	8.9	0	
Edelman [37]	Surg Laparosc Endosc (1995)	5	–	Surgipro	LARS	–	0	
Behrns [44]	J Laparoendosc Surg (1996)	2	10		LPEHR(5), LARS(7)	6	0	0
Trus [38]	J Gastrointest Surg (1997)	1	75		LPEHR(5), LARS(71)	≤ 16	5(7%)	
Huntington [14]	J Am Coll Surg (1997)	8	–	Prolene		8	0	
Paul [12]	Surg Endosc (1997)	3	–	PTFE	LPEHR(2), LARS(1)	10	0	
Willekes [45]	Ann Surg (1997)	30		PTFE	LARS		0	
Frantzides [17]	Surg Endosc (1997)	3	–	PTFE	LARS	≤ 11	0	
Medina [46]	JSLS (1998)	2	18	Goretex	LPEHR(6), LARS(14)	6–48	0	0
Hawasli [47]	Am Surg (1998)	27		Prolene	LARS	1–56	0	
Carlson [36]	J Am Coll Surg (1998)	44	–	Prolene	PEHR	52	0	–
Simpson [48]	Am Surg (1998)	38	–	Dacron	LARS	15	0	
Schulz [49]	Abstract (1998)	161	157	Prolene	LARS		2 (1.2%)	12 (7.1%)
Horgan [50]	Am J Surg (1999)	5	36		LARS		0	0
Wu [51]	Surg Endosc (1999)	6	–	Marlex	LARS			
Carlson [52]	Dig Surg (1999)	15	16	PTFE	LARS	12–36	0	3 (18.8%)
Frantzides [53]	Surg Endosc (1999)	17	18	PTFE	LARS	36	0	3 (16.6%)
Basso [13]	Surg Endosc (2000)	67	65	Prolene	LARS	22.5–48.3	0	9 (13.8%)
Hui [54]	Am Surg (2001)	12	12	Goretex(8), Marlex(2), Prolene(2)	LARS	24–48	0	0

(*continued*)

Table 1 (*continued*)

Author (Ref.)	Publication (year)	Patients (n)		Mesh type	Repair	Follow-up (months)	Recurrence rate	
		Mesh	*Non-mesh*				*Mesh*	*Non-mesh*
Lambert [55]	Pediatr Surg Int (2001)	7		Prolene	LARS	12	0	
Livingston [56]	Am Surg (2001)	10	22	Composix	LARS	1–72	0	3 (13.6%)
Athanasakis [3]	Endoscopy (2001)	3	7	PTFE	LARS	12	0	0
Frantzides [25]	Arch Surg (2002)	36	36	PTFE	LARS	6–72	0	8 (22%)
Meyer [57]	Ann Chir (2002)	10		PTFE(5), Prolene(5)	LARS	8–40	0	
Kamolz [22]	Surg Endosc (2002)	100	100	Prolene	LARS	12	1 (1%)	9 (9%)
Casaccia [18]	Surg Endosc (2002)	8		PTFE		8	0	
Granderath [21]	J Gastrointest Surg (2002)	170	361	Prolene	LARS	12	1 (0.6%)	22 (6.1%)
Morales [58]	Springer (2002)	9	55	PTFE	LARS		1 (1.1%)	3 (5.4%)
Champion [15]	Surg Endosc (2003)	52	–	Prolene	LPEHR	7–60	1 (1.9%)	–
Leeder [59]	Surg Endosc (2003)	14	39	Prolene	LARS	6–89	2 (14%)	3 (7.6%)
Diaz [60]	J Gastrointest Surg (2003)	9	107	Polene, SIS	LARS	30 ± 25	2 (33%)	19 (21%)
Oelschlager [19]	Am J Surg (2003)	9	–	SIS	LARS	3–16	1	
Granderath [24]	Arch Surg (2003)	24	–	Prolene	RELARS	12	0	
Ponsky [61]	Surg Endosc (2003)	1				21	0	
Keidar [16]	Surg Lap End Per Tech (2003)	10	23	Goretex(6), Prolene(4)	LARS	46–76	1 (10%)	4 (18%)
Granderath [23]	Arch Surg (2005)	50	50	Prolene	LARS	12	4 (8%)	13 (26%)

Table 2. Experts experience and recommendations

Surgeon	Mesh type	Recur-rences	Redo-procedures for failed hiatal closure	Mesh related complications (erosion, migration, infection)	Indication for prosthetic hiatal closure	Tension-free vs. additional sutures	Ideal mesh?
Filipi	Gore Dual mesh (PTFE)	0	0	0	(1) Weight >100 lbs (2) Physical jobs (3) Tearing crura introperatively	Simple sutures + Onlay mesh	"C"-shaped with 4 cm inner hole
Basso	Polypropylene	1	1	2 migrations	(1) Hiatal defect >3 cm (2) Weak pillars (3) Stretching pillars	Tension-free	3 × 4 cm polypropylene 6 × 6 cm polypropylene for large hernias
Szold	Goretex, Polypropylene, Composite	3	3	0	(1) All paraesophageal hernias (2) Hiatal defect >4 cm (3) Weak crura	Simple sutures + Onlay mesh	"U" shaped covering the posterior repair
Carlson	Polypropylene, PTFE	0	0	1 esophageal erosion (Polypropylene)	(1) Hiatal defect ≥6 cm	Tension-free	(1) easy to handle (2) benign to visceral surfaces (3) resistant to long-term contraction (4) inexpensive (5) able to adhere to diaphragma (6) noncarcinogenic
Frantzides	PTFE	0	0	0	(1) Hiatal defect >5 cm (2) poor muscle crura quality	Tension-free	Oval shape with 3.5 cm keyhole

References

[1] Dent J, Jones R, Kahrilas P, Talley NJ (2001) Management of gastro-oesophageal reflux disease in general practice. BMJ 322: 344

[2] Spechler SJ (1992) Epidemiology and natural history of gastro-oesophageal reflux disease. Digestion 51: 24

[3] Athanasakis H, Tzortzinis A, Tsiaoussis J, Vassilakis JS, Xynos E (2001) Laparoscopic repair of paraesophageal hernia. Endoscopy 33: 590–594

[4] Hashemi M, Peters JH, DeMeester TR, Huprich JE, Quek M, Hagen JA, Crookes PF, Theisen J, DeMeester SR, Sillin LF, Bremner CG (2000) Laparoscopic repair of large type-III hiatal hernia: objective followup reveals high recurrence rate. J Am Coll Surg 190(5): 553–560; Discussion 560–561

[5] Kuster GG, Gilroy S (1993) Laparoscopic technique for repair of paraesophageal hiatal hernias. J Laparoendosc Surg 3: 331–338

[6] Perdikis G, Hinder RA, Filipi CJ, Walenz T, McBride PJ, Smith SL, Katada N, Klingler PJ (1997) Laparosopic paraesophageal hernia repair. Arch Surg 132: 586–590

[7] Hunter JG, Smith CD, Branum GD et al (1999) Laparoscopic fundoplication failures: patterns of failure and response to fundoplication revision. Ann Surg 230: 595–604

[8] Soper NJ, Dunnegan D (1999) Anatomic fundoplication failure after laparoscopic antireflux surgery. Ann Surg 229: 669–677

[9] Granderath FA, Kamolz T, Schweiger UM, Pointner R (2004) Quality of life, patients satisfaction and surgical outcome after laparoscopic refundoplication: experiences with 100 laparoscopic redo-procedures. Surg Endosc (Suppl 18): O212

[10] Carlson MA, Frantzides CT (2001) Complications and results of primary minimally invasive antireflux procedures: a review of 10,735 reported cases. J Am Coll Surg 193: 428–439

[11] Ponce JF, Barriga R, Martin I, Morales Conde S, Morales S (1998) Prosthetic materials in incisional hernia. Experimental study. Cir Esp 63: 189–194

[12] Paul MG, De Rosa RP, Petrucci PE, Palmer ML, Danovitch SH (1997) Laparoscopic tension-free repair of large paraesophageal hernias. Surg Endosc 11: 303–307

[13] Basso N, DeLeo A, Genco A et al (2000) 360° laparoscopic fundoplication with tension – free hiatoplasty in the treatment of symptomatic gastroesophageal reflux disease. Surg Endosc; 14: 164–169

[14] Huntington TR (1997) Laparoscopic mesh repair of the oesophageal hiatus. J Am Coll Surg 184: 399–401

[15] Champion JK, Rock D (2003) Laparoscopic mesh cruro plasty for large paraesophageal hernias. Surg Endosc 17: 551–553

[16] Keidar A, Szold A (2003) Laparoscopic repair of paraesophageal hernia with selective use of mesh. Surg Laparosc Endosc 13: 149–154

[17] Frantzides CT, Carlson MA (1997) Prosthetic reinforcement of posterior cruroplasty during laparoscopic hiatal herniorraphy. Surg Endosc 11: 769–771

[18] Casaccia M, Torelli P, Panaro F, Cavaliere D, Ventura A, Valente U (2002) Laparoscopic physiologic hiatoplasty for hiatal hernia: new composite "A" shaped mesh. Surg Endosc 16: 1441–1445

[19] Oelschlager BK, Barreca M, Chang L, Pellegrini CA (2003) The use of small intestine submucosa in the repair of paraesophageal hernias: initial observations of a new technique. Am J Surg 186(1): 4–8

[20] Varga G, Cseke L, Kalmar K, Horvath OP (2004) Prevention of recurrence by reinforcement of hiatal closure using ligamentum teres in laparoscopic repair of large hiatal hernias. Surg Endosc 18: 1051–1053

[21] Granderath FA, Schweiger UM, Kamolz T et al (2002) Laparoscopic antireflux surgery with routine mesh-hiatoplasty in the treatment of gastroesophageal reflux disease. J Gastrointest Surg 6: 347–353

[22] Kamolz T, Granderath FA, Bammer T, Pasiut M, Pointner R (2002) Dysphagia and quality of life after laparoscopic Nissen fundoplication in patients with and without prosthetic reinforcement of the hiatal crura. Surg Endosc 16(4): 572–577

[23] Granderath FA, Schweiger UM, Kamolz T, Asche KU, Pointner R (2005) Laparoscopic Nissen fundoplication with prosthetic hiatal closure reduces postoperative intrathoracic wrap herniation: Preliminary results of a prospective randomized functional and clinical study. Arch Surg 140: 40–48

[24] Granderath FA, Kamolz T, Schweiger UM et al (2003) Laparoscopic refundoplication with prosthetic hiatal closure for recurrent hiatal hernia after primary failed antireflux surgery. Arch Surg 138: 902–907

[25] Frantzides CT, Madan AK, Carlson MA et al (2002) A prospective, randomized trial of laparoscopic polytetraflouroethylene (PTFE) patch repair vs simple cruroplasty for large hiatal hernia. Arch Surg 137: 649–653

[26] Carlson MA, Condon RE, Ludwig KA, Schulte WJ (1998) Management of intrathoracic stomach with polypropylene mesh prosthesis reinforced transabdominal hiatus hernia repair. J Am Coll Surg 187(3): 227–230

[27] Voyles CR, Richardson JD, Bland KI et al (1981) Emergency abdominal wall reconstruction with polypropylene

mesh: short-term benefits versus long-term complications. Ann Surg 194(2): 219–223
[28] Frantzides CT, Carlson MA (2001) Paraesophageal herniation. In: Mastery of surgery, vol. 1 (Baker RJ, Fischer JE, eds). Philadelphia: Lippincott Williams & Wilkins, pp 721–736
[29] Wantz GE (1991) Atlas of hernia surgery. New York: Raven Press
[30] Heniford BT, Park A, Ramshaw BJ, Voeller G (2003) Laparoscopic repair of ventral hernias: nine years' experience with 850 consecutive hernias. Ann Surg 238(3): 391–399; Discussion 399–400
[31] Kemppainen E, Kiviluoto T (2000) Fatal cardiac tamponade after emergency tension-free repair of a large paraesophageal hernia. Surg Endosc 14(6): 593
[32] Amid PK (2004) Shrinkage: Fake or Fact? In: Meshes: benefits and risks (Schumpelick V, Nyhus LM, eds). Berlin: Springer, pp 198–206
[33] Baladas HG, Smith GS, Richardson MA, Dempsey MB, Falk GL (2000) Esophagogastric fistula secondary to teflon pledget: a rare complication following laparoscopic fundoplication. Dis Esophagus 13: 72–74
[34] Arendt T, Stuber E, Monig H, Folsch UR, Katsoulis S (2000) Dysphagia due to transmural migration of surgical material into the esophagus nine years after Nissen fundoplication. Gastrointestinal Endosc 51: 607–610
[35] Dally E, Falt GL (2004) Teflon pledget reinforced fundoplication causes symptomatic gastric and esophageal lumenal penetration Am J Surg 187: 226–229
[36] Carlson MA, Condon RE, Ludwig KA, Schulte WJ (1998) Management of intrathoracic stomach with polypropylene mesh prosthesis reinforced transabdominal hiatus hernia repair. J Am Coll Surg 187: 227–230
[37] Edelman DS (1995) Laparoscopic paraesophageal hernia repair with mesh. Surg Laparosc Endosc 5: 32–37
[38] Trus TL, Bax T, Richardson WS, Branum GD, Mauren SJ, Swanstrom LL, Hunter JG (1997) Complications of laparoscopic paraesophageal hernia repair. J Gastrointest Surg 1: 221–228
[39] Van der Peet DL, Klinkerberg-Knol EC, Alonso A, Sietses C, Eijsbouts QAJ, Cuesta MA (2000) Laparoscopic treatment of large paraesophageal hernias. Surg Endosc 14: 1015–1018
[40] Casabella F, Sinanan M, Horgan S, Pellegrini CA (1996) Systematic use of gastric fundoplication in laparoscopic repair of paraesophageal hernias. Am J Surg 171: 485–489
[41] Coluccio G, Ponzio S, Ambu V, Tramontano R, Cuomo G (2000) Dislocation into the cardial lumen of a PTFE prosthesis used in the treatment of voluminous hiatal sliding hernia, a case report. Minerva Chir 55: 341–345
[42] Pitcher DE, Curet MJ, Vogt DM, Mason J, Zucker KA (1995) Successful repair of praesophageal hernia. Arch Surg 130: 590–596
[43] Oddsdottir M, Franco AL, Laycock WA, Waring JP, Hunter JG (1995) Laparoscopic repair of paraesophageal hernia. New access, old technique. Surg Endosc 9: 164–168
[44] Behrns KE, Schlinkert RT (1996) Laparoscopic management of paraesophageal hernia: early results. J Laparoendosc Surg 6: 311–317
[45] Willekes CL, Edoga JK, Freeza EE (1997) Laparoscopic repair of paraesophageal hernia. Ann Surg 225: 31–38
[46] Medina L, Peetz M, Ratzer E, Fenoglio M (1998) Laparoscopic paraesophageal hernia repair. JSLS 2: 269–272
[47] Hawasli A, Zonca S (1998) Laparoscopic repair of paraesophageal hiatal hernia. Am Surg 64: 703–710
[48] Simpson B, Ricketts RR, Parker PM (1998) Prosthetic patch stabilization of crural repair in antireflux surgery in children. Am Surg 64: 67–70
[49] Schulz HG (1998) Rezidivrate nach laparoskopischer Antirefluxoperation mit und ohne Prolenenetzplastik bei 318 Fällen – erste Ergebnisse. 7. Jahreskongress der Gesellschaft für Gastroenterologie Westfalen
[50] Horgan S, Eubanks TR, Jacobsen G, Omelanczuk P, Pellegrini CA (1999) Repair of paraesophageal hernias. Am J Surg 177: 354–358
[51] Wu JS, Dunnegan DL, Soper NJ (1999) Clinical and radiologic assessment of laparoscopic paraesophageal hernia repair. Surg Endosc 13: 497–502
[52] Carlson MA, Richards CG, Frantzides CT (1999) Laparoscopic prosthetic reinforcement of hiatal herniorrhaphy. Dig Surg 16: 407–410
[53] Frantzides CT, Richards CG, Carlson MA (1999) Laparoscopic repair of large hiatal hernia with polytetrafluoroethylene. Surg Endosc 13: 906–908
[54] Hui TT, David T, Spyrou M, Phillips EH (2001) Mesh crural repair of large paraesophageal hiatal hernias. Am Surg 67: 1170–1174
[55] Lambert AW, Huddart SN (2001) Mesh hiatal reinforcement in Nissen funduplication. Pediatr Surg Int 17: 491–492
[56] Livingston CD, Lamar Jones H, Askew RE, Victor BE, Askew RE (2001) Laparscopic hiatal hernia repair in patients with poor esophageal motility or paraesophageal herniation. Am Surg 67: 987–991
[57] Meyer C, Bufffler A, Rohr S, Lima MC (2002) Le traitement laparoscopique des hernies hiatales de gran taille avec mise en place d'une prothese. A propos de dix cas. Ann Chir 127: 257–261

[58] Morales Conde S, Ponce JF, Morales Mendez S (2002) Paraesophageal hernia: technique and method of fixation a mesh by laparoscopy. In: Laparoscopic ventral hernia repair (Morales-Conded S, ed). Springer

[59] Leeder PC, Smith G, Dehn TC (2003) Laparoscopic management of large paraesophageal hiatal hernia. Surg Endosc 17: 1372–1375

[60] Díaz S, Brunt M, Klingensmith ME, Frisella PM, Soper NJ (2003) Laparoscopic paraesophageal hernia repair, a challenging operation: medium-term outcome of 116 patients. J Gastroint Surg 7: 59–67

[61] Ponsky J, Rosen M, Fanning A, Malm J (2003) Anterior gastropexy may reduce the recurrence after laparoscopic paraesophageal hernia repair. Surg Endosc 17: 1036–1041